

# Histological and immunohistochemical features of medullary breast cancer

ANATOLII ROMANIUK<sup>1</sup>, MYKOLA LYNDIN<sup>1</sup>, VLADYSLAV SIKORA<sup>1</sup>, YULIIA LYNDINA<sup>2</sup>,  
KATERYNA PANASOVSKA<sup>3</sup>

<sup>1</sup>Sumy State University, Department of Pathology, Ukraine

<sup>2</sup>Sumy State University, Department of Anatomy, Ukraine

<sup>3</sup>Sumy State University, Ukraine

**Corresponding author:** Vladyslav Sikora, MD, Sumy, st. Privokzalnaya, 31, Ukraine; Phone: +38 050 727 61 93  
E-mail: vlad-sikora@ukr.net

**Abstract:** Disputes take place among many scientists about the position of MC in the classification of breast cancer. Some say that this kind of tumor is a sign of invasive ductal carcinoma (IDC). Instead, most of modern researchers distinguish MC of the breast as a separate nosological unit.

Primarily there were selected 20 cases of MC and 10 cases of IDC (as control group). The immunohistochemical study revealed the presence of ER, PR, HER2/neo, p53, Ki-67, MMP1 and E-cadherin receptors.

In the study of receptor status of tumors it was observed that 100% of MC cases were estrogen-, progesterone- and HER2/neu negative. The status of tumors on receptor p53 and Ki-67 was as follows: p53+ status had 80% and Ki-67+ had 85% of tissues of MC. In 75% of cases MC cells expressed marker of adhesion and in 100% of cases cells were receptor-negative for expression of MMP1.

The data of the study show that the invasive ductal carcinoma and medullary carcinoma are completely independent and different types of malignancy in the breast. The favorable behavior of medullary cancer is associated with expression of E-cadherin receptors, which are essentially adhesion factor and absence of MMP1 which are factors of metastatic potential of the tumor.

**Key words:** breast cancer, medullary carcinoma, invasive ductal carcinoma.

## Introduction

There are more than 50 histological types of breast cancer (BC). According to research data the medullary carcinoma (MC) estimates from 1% to 7% among them and sometimes is up to 10% [1]. The average age of patients ranges from 45 to 54 years old [2]. Women younger

than 35 years old make up 10%. The MC cases more often occur with Japanese and African-Americans women compared to women of the white race. Bilateral damages are observed in 3–18%, the multicentric character of growth in one breast is indicated in 10% of cases [3]. It should be noted that neither of studied groups has reported about the MC case in men [4].

Disputes take place among many scientists about the position of MC in the classification of breast cancer. Some say that this kind of tumor is a sign of invasive ductal carcinoma (IDC) [5]. Instead, most of modern researchers distinguish MC of the breast as a separate nosological unit. Discrepancy of highly malignant morphological picture and relatively favorable behavior of the tumor distinguishes it from the total number of infiltrating carcinomas. Having morphological features of a low differentiated tumor with marked nuclear and cellular atypia and a high level of proliferation, MC, in most cases, had to be classified to the third degree of malignancy according to Scarff-Bloom-Richardson system, but the biological behavior of the tumor, however, is less aggressive [6].

The immunohistochemical investigations allow defining more precisely the type of breast cancer, to prescribe purposeful treatment and to predict the course of illness in each determined case by the identification of receptors in breast tumor tissue. The presence of estrogen receptors (ER), progesterone receptors (PR) and human epidermal growth factor receptor 2 (HER2/neo) determines the prognosis and sensitivity of tumor to antihormonal and monoclonal therapy; it also correlates with the histological differentiation of the tumor. The degree of receptors expression for steroid hormones is inversely proportional to the degree of aneuploidy of cancer cells [7].

The presence of factors that regulate programmed cell death (proapoptotic marker p53) and the proliferative activity (marker Ki-67) determines the prognosis of BC [8]. The accumulation of p53 indicates the aggressive behavior of the tumor, a shorter disease-free and non-metastasis period, worse prognosis and the necessity of more aggressive therapy. The study of non-histone protein Ki-67 allows to determine “hidden” proliferative potential of the tumor and to assess the degree of malignancy, to divide patients into groups with relatively favorable and unfavorable prognosis [9].

Metastatic readiness of tumor cells is determined by the presence of E-cadherin receptors and matrix metalloproteinase 1 (MMP1). E-cadherin is a membrane protein, which participates in homophylic interactions, forming intercellular contacts [10]. It is involved into the regulatory mechanisms of intercellular adhesion, cell motility and proliferation of epithelial cells, plays a potential antagonistic role in the ability of cells to invasion [11]. MMR1 is the collagenase. Hydrolyzing collagen of vascular walls and the surrounding matrix environment, they allow tumor’s cells to spread and to metastasize [12].

According to various sources the lack of ER and PR expression is typical for MC tumor cells, while in some works there were not found any difference in the levels of the expression of ER and PR in comparison with IDC [13]. The percentage of HER2/neo expression in MC is ranged from 10% to 33%, while other investigations have found that all MC tumors had been HER2/neo negative. The frequency of monitoring of p53 in MC tumors is different too. Some scientists argue that p53 is found in 100% of cases of MC, others see no difference compared with IDC [14].

At present, there are no simple and clear morphological criteria that would allow eliminate the risk of over- and underdiagnosis of typical medullary cancer. Thus, the objectives of this paper are as follows: to establish peculiarities of medullary breast cancer course, comparing it with invasive ductal cancer, taking into account the expression of ER, PR, HER2/neu, p53, Ki-67, E-cadherin and MMR1 by tumor cells.

### **Material and methods**

Primarily there were selected 20 cases of MC and 10 cases of IDC (as control group). The criteria of MP selection were 5 signs according to the recommendation of World Health Organization Classification of Tumours of the breast: syncytial structure of tumors, the absence of tubular and glandular structures, lymphoplasmacytic infiltration, high-grade polymorphism and histological circumscription or pushing margin.

The material for the immunohistochemical study was fixed in 10% neutral formalin for 24 hours, and then paraffin blocks were made of it. Then sections with the thickness of 3–4 mm were made and they were subjected to the standard process of dehydration in xylene and alcohols of rising concentration. The monoclonal antibodies (firm «Dako») in different dilutions were used for determination the expression of receptors:

- the antibodies for ER (clone SR1) and PR (clone SR2) with assessment of their expression according to DC Allred recommendations (taking into account the proportion of stained nuclei and the intensity of their staining) [15] were used for identifying receptors to steroid hormones;
- the antibodies for HER2/neo (clone SR3) were used to determine the expression of epidermal growth factor receptors. We performed evaluation of reactions using the point scale — 0, 1+, 2+, 3+, which were developed by the manufacturer and were approved by FDA [16];
- the cell's proliferative activity was assessed taking into account the number of positively stained cells;
- p53 antibodies (clone SR5) were used for determination the pro-apoptotic receptor. Recommendations of the American research laboratory were used for determination p53-receptor status: a positive result was defined as distinct nuclear staining in at least 10% of the carcinoma cells;
- E-cadherin antibodies (clone SPM471) were used for determination the adhesive receptors and MMR1 polyclonal antibodies were used for determination the collagenase activity of tumor. The results were evaluated by semiquantitative method: 0 points — no reaction, 1 point — poor response, 2 points — moderate reaction, 3 points — severe reaction.

Mathematical calculations were done using Microsoft Excel 2010 with 12.0.5 Attestat option. We found such indicators as chi-squared Pearson's test, Student's T-criterion (with statistical significance  $p < 0.05$ ).

## Research results

Breast cancer in Sumy, as in Ukraine and in most countries of the world, progresses and nowadays occupies the first place in the structure of women morbidity (26–28% of all cancers). Among all types of breast cancer, MC accounts for about 4%.

Macroscopically it is presented by clearly defined, moderately dense tumor foci of round form. The foci is 2–3 cm in diameter, less dense than other forms of cancers (tumors of soft consistency, similar to brain tissue), has signs of fibrosis in the peripheral zone, which can simulate the capsule. Sometimes the tumor boundaries are unclear, due to the presence of lymphoid infiltration. The surface of the cut is smooth, sometimes slightly convex, juicy, matte, with gray color, small hemorrhages and foci of necrosis. Histological examination of the tumor is characterized by syncytial growth (more than 75% of the cut), the absence of glands and tubes (even in small amounts), with expressed lymphoplasmacytic infiltration of the stroma (Fig. 1), moderate or severe cellular polymorphism, which corresponds to a moderate or low level of histological differentiation (G2 or G3). The edges of the tumor can be compressed by peripheral fibrous tissue in the form of pseudo capsule.

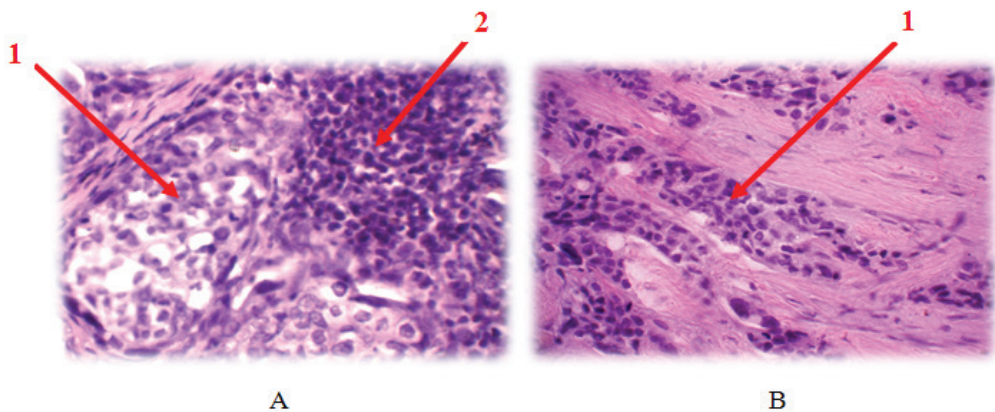


Fig. 1. Histologic picture of MC (A) and IDC (B) of mammary gland; 1 — tumor cells, 2 — lymphocytic infiltration. Staining with hematoxylin-eosin. Increase  $\times 300$ .

IDC of mammary gland is macroscopically characterized by tumor foci, which can be divided into two groups: stellate (infiltrative) or clearly defined (round) shape. Consistence is different, oftener more denser than for MC. Due to infiltrative growth of the carcinoma the boundaries of the tumor are not clear. It has gray-yellow color with areas of secondary changes such as mucinization, calcification, hemorrhages and necrosis. In cases of high histological differentiation of tumor growth cancer cells form mainly glandular, tubular structures. With the decrease of cancer differentiation the volume of stroma decreases, the cancer cells form a solid field. Sometimes relatively isolated accumulations of tumor cells are dominated. In most cases the tumor tissue is composed of large cells, which have lost the opportunity to the typical distribution of epithelium in the form of layers, but retain

tends to adhesion. In the cells there is well visible cytoplasm and large polymorphic nucleus with several nucleoli. Pathological mitosis is expressed in the different stages with ugly multi-cells formation.

In the study of receptor status of tumors (Fig. 2) it was observed that 100% of MC cases were estrogen-, progesterone- and HER2/neu negative. While researching, two estrogen-positive cases (in pre-diagnosed MC of mammary gland) were attributed to invasive cancer with medullary component due to the presence of single glandular structures formed by cancer cells.

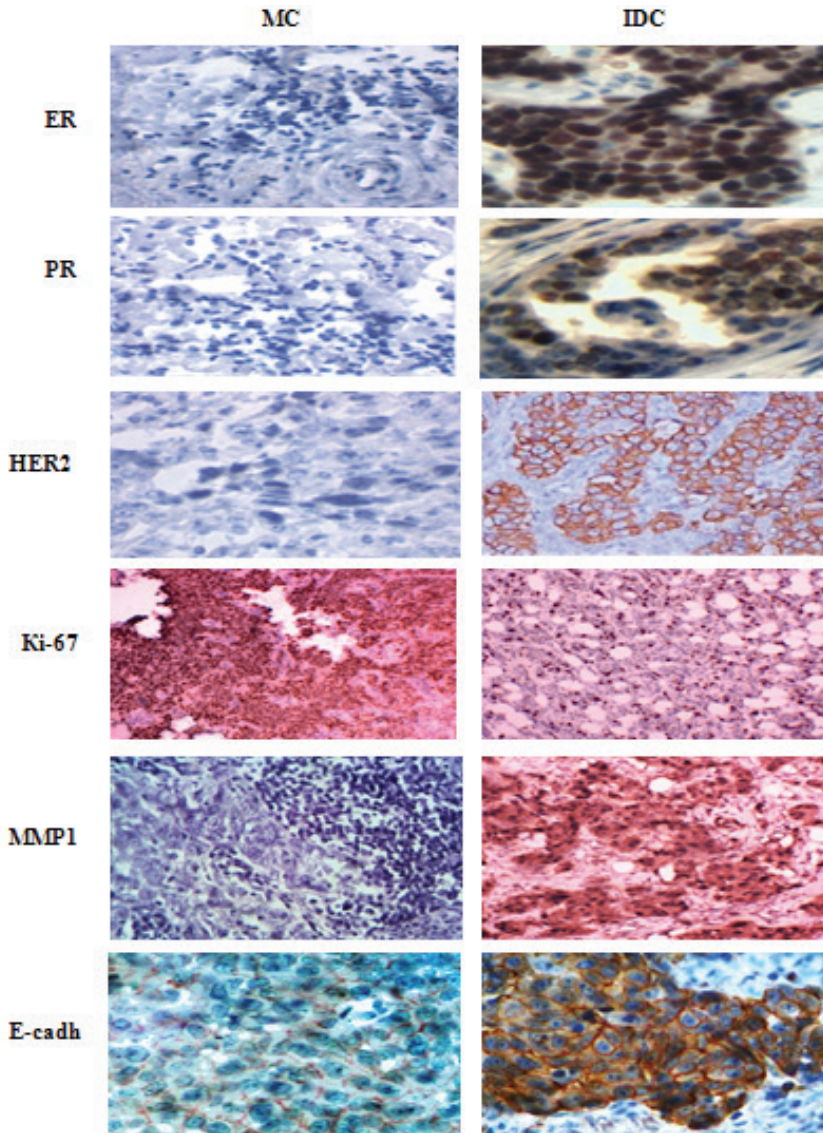


Fig. 2. Immunohistochemical study of MC and IDC.



The status of tumors on receptor p53 and Ki-67 was as follows: p53+ status had 80%, 85% of tumors had level of proliferative activity more than 10% (Ki-67 expression). With respect to receptor expression MMR1 and E-cadherin, the results were completely opposite. In 75% of cases MC cells expressed marker of adhesion in the thick solid line form and in 100% of cases cells were receptor-negative for expression of MMP1. Regarding IDC (Fig. 2), results of immunohistochemical studies were different compared to MC of mammary gland (Table 1): the tumor cells are more expressed p53 ( $p < 0.05$ ), in the majority of cases ER, PR and MMP1 were present, E-cadherin expression was presented as fragments thin lines.

**Table1.** Differential criteria of diagnosis of medullary cancer and invasive ductal breast cancer.

Characteristics	IDC	MC
Consistency of tumor node	Different, oftener dense	Soft
Shape of the node	Star-shaped, sometimes round	Round
Boundaries of tumor	Fuzzy	Clear outlined
Secondary changes	Often	Rarely
The degree of cell differentiation	Different, from low to highly differentiated	Low differentiated
Lymphoplasmacytic infiltration	±	+
The presence of stroma	±	-
The formation by cells of glands and ducts	+	-
Expression of receptors for steroid hormones		
ER	80%	-
PR	60%	-
Expression of HER2/neu	25%	-
Expression of p53	20%	80%
Expression of Ki-67	75%	85%
Expression of E-cadherin	±	75%
Expression of MMP1	60%	-

Note: "+" — indicates that the sign presents in the definite type of cancer, "-" — the sign is absent.

## Discussion

The low level of medullary cancer diagnosis is explained by the lack of clear histological and immunohistological criteria in diagnosis. Sometimes it is difficult to evaluate in practice such diagnostic features as state of verges [5]. Syncytial type of tumor cell growth, lack of tubular structures, lymphocytoplasmocytic infiltration, rarity (less than 25%) of necrosis in the tumor should be obvious and characteristic features of MC [6].

Analyzing the opinion that MC is a form of IDC, and comparing with data obtained during the morphological, histological and immunohistochemical study, we can conclude that these two types of tumor are two different tumors. Tumor cells of MC have G2-G3 degree of malignancy, and more often than other forms of cancer express p53, Ki-67, which are prognostically unfavorable-receptors and do not express prognostically favorable steroid hormone receptors [13, 14]. Instead, the known fact, this tumor has favorable behavior [6]. Exploring receptor E-cadherin, which is antimetastatic factor, we noted the possibility of expression this protein by MC cells.

Instead, the lack of receptors of MMP1 was found. They are used to measure the capacity to metastasize of breast cancer [12]. Combining the last two facts, it is clear, as prognostically unfavorable tumor has congenial passing with the absence of metastases in the nearest lymph nodes [11, 12].

Differential diagnostic criteria for two types of breast cancers are shown in Table 1, which includes macroscopical, morphological, histological and immunohistochemical characteristics of the tumors.

## Conclusions

The data of the study show that the invasive ductal carcinoma and medullary carcinoma are completely independent and different types of malignancy in the breast. The medullary cancer tissue has high degree of tumor tissue malignancy, higher levels of cell proliferative activity, the degree of p53 and E-cadherin expression and the lack of MMR1, ER and PR. The favorable behavior of medullary cancer is associated with expression of E-cadherin receptors, which are essentially adhesion factor and absence of MMP1 which are factors of metastatic potential of the tumor.

## Conflict of interest

None declared.

## References

1. Park I., Kim J., Kim M., Bae S.Y., Lee S.K., Kil W.H., Lee J.E., Nam S.J.: Comparison of the Characteristics of Medullary Breast Carcinoma and Invasive Ductal Carcinoma. *Breast Cancer*. 2013; 16 (4): 417–425.
2. Huober J., Gelber S., Goldhirsch A., Coates A.S., Viale G., Öhlschlegel C., Price K.N., Gelber R.D., Regan M.M., Thürlimann B.: Prognosis of medullary breast cancer: analysis of 13 International Breast Cancer Study Group (IBCSG) trials. *Ann Oncol*. 2012; 23: 2843–2851.
3. Li C.I.: Risk of mortality by histologic type of breast cancer in the United States. *Horm Cancer*. 2010; 1: 156–165.
4. Goss P.E., Reid C., Pintilie M., Lim R., Miller N.: Male breast carcinoma: a review of 229 patients who presented to the Princess Margaret Hospital during 40 years: 1955–1996. *Cancer*. 1999; 85 (3): 629–639.
5. Ridolfi R.L., Rosen P.P., Port A., Kinne D., Mike V.: Medullary carcinoma of the breast: a clinicopathology study with a 10-year follow up. *Cancer*. 1977; 40: 1365–1385.

6. Bloom H.J., Richardson W.W., Field J.R.: Host resistance and survival in carcinoma of breast: a study of 104 cases of medullary carcinoma in a series of 1,411 cases of breast cancer followed for 20 years. *Br Med J.* 1970; 3: 181–188.
7. Vo T., Xing Y., Meric-Bernstam F., Mirza N., Vlastos G., Symmans W.F.: Long-term outcomes in patients with mucinous, medullary, tubular, and invasive ductal carcinomas after lumpectomy. *Am J Surg.* 2007; 194: 527–531.
8. Shapochka D.O., Zaletok S.P., Gnidyuk M.I.: Relationship between NF- $\kappa$ B, ER, PR, Her2/neu, Ki67, p53 expression in human breast cancer. *Exp Oncol.* 2012; 34 (4): 358–363.
9. Payandeh M., Sadeghi M., Fekri A., Sadeghi E.: P 53 mutation compared with Ki-67 markerin metastasis of breast cancer in west Iran. *Journal of Solid Tumors.* 2014; 4 (3): 4–9.
10. Esteva F.G., Hortobagyi G.N.: Prognostic markers in early breast cancer. *Breast Cancer Res.* 2004; 6 (3): 109–118.
11. Suciuc C., Cimpean A.M., Mureşan A.M., et al.: E-cadherin expression in invasive breast cancer. *Romanian Journal of Morphology and Embryology.* 2008; 4: 517–523.
12. Mannello F.: What does matrix metalloproteinase-1 expression in patients with breast cancer really tell us? *BMC Medicine.* 2011; 9: 95.
13. Martinez S.R., Beal S.H., Canter R.J., Chen S.L., Khatri V.P., Bold R.J.: Medullary carcinoma of the breast: a population-based perspective. *Med Oncol.* 2011; 28: 738–744.
14. Matsubara N., Mukai H., Itoh K., Nagai S.: Prognostic impact of Ki-67 overexpression in subgroups categorized according to St. Gallen with early stage breast cancer. *Oncology.* 2011; 81: 345–352.
15. Allred D.C., Harvey J.M., Berardo M., Clark G.M.: Prognostic and predictive factors in breast cancer by immunohistochemical analysis. *Mod Path.* 1998; 11: 155–168.
16. Wolff A.C., Hammond M.E., Schwartz J.N.: American Society of Clinical Oncology/College of American Pathologists guideline recommendations for human epidermal growth factor receptor 2 testing in breast cancer. *J Clin Oncol.* 2007; 25: 118–145.